

Veterinary Diagnostic Services Lab Notes

March 2025

Volume 3, Issue 1



Case of Ovine Abortion – Hyperplastic Goiter

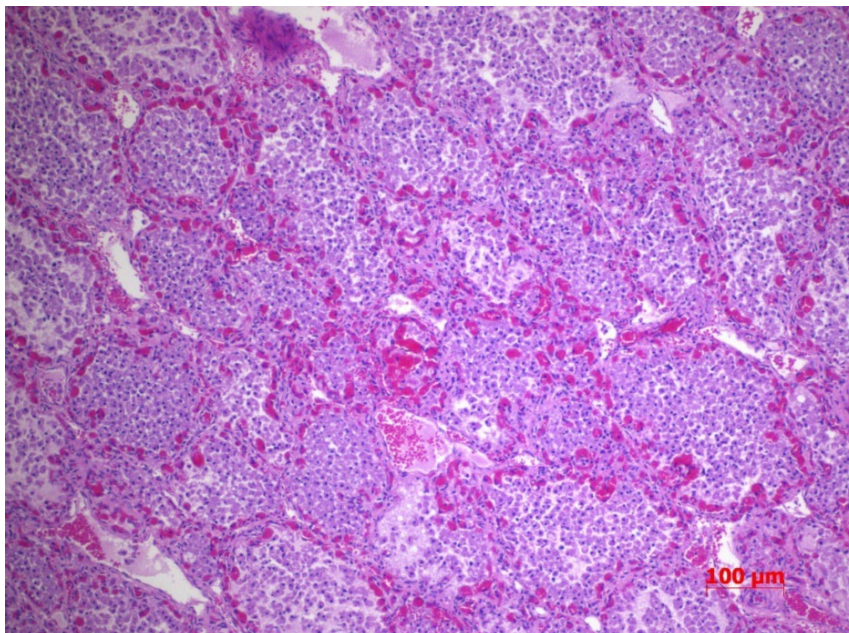
Dr. Marek Tomczyk, DVM, Dipl. Anat. Path, VDS Pathologist

During late March, a flock of 12 ewes experienced lambing issues which involved 23 dead and nine live, but weak, lambs. Of the three lambs submitted to the Veterinary Diagnostic Services (VDS), all three submissions had enlarged thyroid glands and two were born prematurely.

The necropsy of one aborted lamb revealed a female in good body condition, weighing 2.5kg and having a crown-rump length of 36cm. The skin was covered with hair, but incisors had not erupted.

The internal adipose deposits were present. Bilaterally, the thyroid gland was markedly enlarged and weighed 31.6 grams. The lungs were not aerated and remaining organs were grossly unremarkable.

On histopathology of the thyroid gland, the thyroid follicles varied markedly in size and multiple follicles were collapsed or expanded. Multiple thyroid follicles were lined by hypertrophied or hyperplastic lining cells, with many not containing colloid. Focally, the periphery follicles contained sloughed cells admixed with macrophages. The follicular cells were larger cuboidal and often filled the entire follicle. Marked vascular congestion was also noted.



Picture (above): Histologic image of the thyroid gland (x10), demonstrating follicles filled with hypertrophied cells.

Holiday Closures

VDS will be closed on

Good Friday – April 18, 2025

Easter Monday – April 21, 2025

Victoria Day – May 19, 2025

VDS Team

Dr. Glen Duizer – Chief Veterinary Officer

Dr. Lisa Joachim – Acting Provincial Veterinarian – Animal Welfare

Dr. Md Niaz Rahim – Chief Scientific Officer

Dr. Neil Pople – Anatomic Pathologist/ Veterinary Microbiologist

Dr. Marek Tomczyk – Anatomic Pathologist

Dr. Brenda Bryan – Anatomic Pathologist

Dr. Vasyl Shpyrka – Diagnostic Pathologist

Dr. Karlyn Bland – Clinical Pathologist

Shannon Korosec – Supervisor, Microbiology

Tracy Scammell-LaFleur – Supervisor, Virology

Rhonda Gregoire – Supervisor, Clinical Pathology

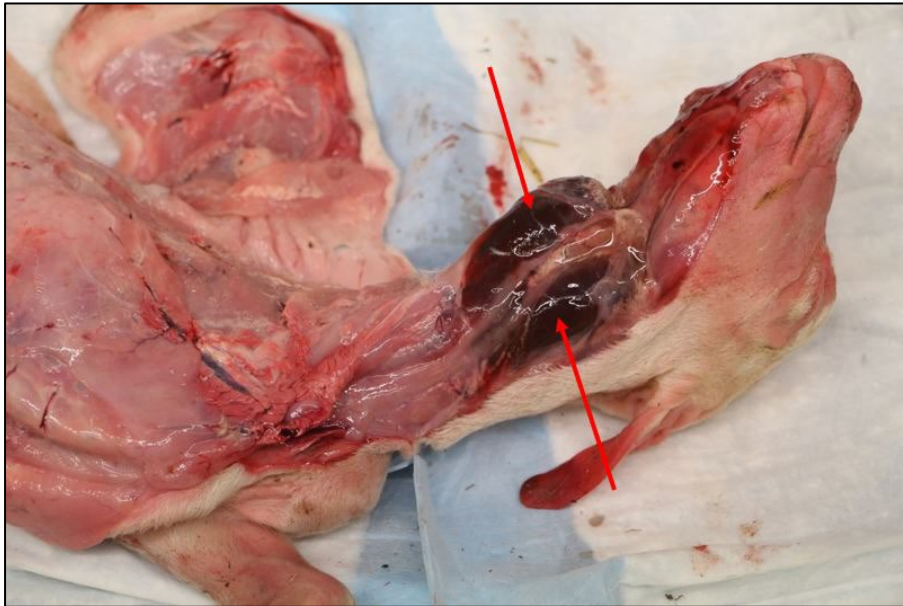
Agnieszka Gigiel – Supervisor, Accessioning

Genedine Quisumbing – Quality Assurance Officer

Sharon Niebel – SAP/Revenue Clerk

Lindsay McDonald Dickson – SAP Clerk

Barb Bednarski – Client Services Coordinator/Reception



Picture (above): Aborted ovine fetus. Red arrows indicate enlarged thyroid glands.

Bacteriology and polymerase chain reaction (PCR) tests for common ovine abortion pathogens, *Chlamydophila abortus*, *Coxiella burnetii* and *Toxoplasma gondii*, were negative.

A final diagnosis of severe, hyperplastic goiter was made in the submitted lambs.

The enlarged thyroid glands (goiter) were obvious on physical examination. Non-neoplastic and non-inflammatory enlargements of the thyroid gland may develop in all domestic mammals, as well as birds. The enlargement can be benign or pathological. Goiter must be differentiated from other causes of upper neck swelling, including salivary gland or lymph node enlargement.

The histopathological finding of hyperplasia in the cells lining the epithelium of the thyroid follicles was consistent with hyperplastic goiter, likely due to iodine deficiency in this case.


Common causes of goiter may include the following:

- iodine deficiency or excess
- ingestion of goitrogenic plants, e.g., plants containing substance(s) that interfere with thyroid hormone production
- hereditary factors
- congenital hypothyroidism and dysmaturity syndrome

Iodine is a component in thyroid hormones, thyroxine and triiodothyronine. Iodine insufficiency impairs the ability of the thyroid to make these hormones. With lower concentrations of circulating thyroid hormones, the pituitary gland secretes more thyroid-stimulating hormone (TSH), which results in hyperplasia of the thyroid gland and subsequent development of a goiter.

Iodine deficiency signs include goitre, reduced fertility and reproductive performance, stillbirths, reduced birth weight with brain retardation, delayed skeletal maturation and wool growth, and decreased growth rate.

Pet Spotlight: Isla



Isla, a Scottish Highland heifer belonging to our Animal Health and Welfare Specialist, Bryan McLean, is excited for spring. She also enjoys everything bagels, being brushed and harassing her donkey friend, Gladys!

We love sharing photos!

We encourage VDS clients and Animal Health and Welfare staff to send any great animal photos or Manitoba moments our way to share with the veterinary community.

Photos can be sent to chiefveterinaryoffice@gov.mb.ca with the subject "VDS Lab Notes Pet Photos."

VDS Dashboard

Visit here for the latest information on case counts, tests conducted and pathology diagnoses.

Highly Pathogenic Avian Influenza – Not Just a Concern for Birds and Dairy Cows

Dr. Deanne Wilkinson, DVM, Extension Veterinarian, MB Agriculture

Since the avian influenza outbreak began in 2022, it became apparent that the commonly circulating strain has the affinity to infect a multitude of domestic species and wildlife. Numerous species of marine mammal, felids, and other wildlife, including red foxes, striped skunks and house mice, have tested positive for highly pathogenic avian influenza (HPAI) H5N1. One of the most affected domestic species is the beloved cat. Felids, in general, have very acute, often severe, symptoms after infection and mortality rates can be significant.

Domestic cats have been exposed to H5N1 through contact with infected wild birds, as well as consumption of raw milk and commercial raw pet food diets containing the virus. Pasteurization and proper cooking of meat will inactivate the virus, meaning the risk of infection can be minimized in many instances. Most recently, infected house cats have been identified from homes of dairy farm staff that were working with infected dairy or handled raw milk. This means that humans or contaminated clothing can likely transmit disease to cats, but because H5N1 is not currently in Canadian dairy herds, the risk of this form of transmission is currently minimal.

Small animal veterinarians are encouraged to keep HPAI on their list of differentials when encountering sick pets, especially those who have had access to the outdoors, dead birds, or are living on dairy farms. Typical signs in cats include:

- generalized illness, including inappetence, fever and lethargy
- neurologic signs, including ataxia, tremors, seizures, blindness
- severe depression
- significant ocular and nasal discharge, conjunctivitis
- respiratory signs, including coughing, sneezing, tachypnea (increased respiratory rate), and difficulties breathing

Because the clinical presentation of H5N1 is very similar to rabies, practitioners or owners observing the above signs in cats should contact the Manitoba Rabies Line at 1-204-470-1108, who will determine how to proceed with diagnostic testing.

H5N1 infection in cats played a critical role in identifying HPAI as the cause of the mystery disease in Texas dairy cattle. As diagnostic laboratories worked tirelessly to determine why herds of dairy cows were experiencing a sudden drop in milk production and inappetence, veterinarians treating the affected farms sent videos of neurologic farm cats to the diagnosticians. With the knowledge that H5N1 causes severe disease in cats, they tested the cats and dairy cattle for H5N1. Although the work of food animal and small animal practitioners does not often seem related, H5N1 has demonstrated the interconnectedness of the profession and reminds us of the One Health impacts of veterinary work.

Did You Know?

Manitoba is the Bacon Capital of Canada. Winnipeg is home to the country's largest bacon processing facility, producing over 38 million kilograms of bacon per year.

Veterinary Diagnostic Services Contact Information

Accounts Payable:
agrinvoices@gov.mb.ca

Clinical Pathology:
clinpath@gov.mb.ca

Microbiology (Bacteriology/
Mycology/Parasitology):
microbiology@gov.mb.ca

Virology (PCR/Molecular
Diagnostics/Serology):
virology@gov.mb.ca

545 University Crescent
Winnipeg, Manitoba R3T 5S6

Phone: 204-945-8220

Email: vetlab@gov.mb.ca

Web: manitoba.ca/agriculture/vds

Keep up with Manitoba Agriculture

Visit our website:
manitoba.ca/agriculture

Follow us on X (formerly Twitter):
twitter.com/MBGovAg

View our videos on YouTube:
youtube.com/ManitobaAgriculture
[Subscribe](#) to our newsletter